Abhandlung

M. Songül Alpaslan-Roodenberg*, Jacob Roodenberg*

In the light of new data: The population of the first farming communities in the eastern Marmara region

https://doi.org/10.1515/pz-2020-0004

Zusammenfassung: Nach einigen Jahrzehnten osteologischer Analysen liefert diese Studie eine Bewertung anthropologischer Daten, die in vier frühen bäuerlichen Gemeinschaften gewonnen wurden, nämlich Ilıpınar, Menteşe, Barcın und Aktopraklık. Alle Fundorte befinden sich in den Seebecken südöstlich des Marmarameers. Verschiedene Aspekte wie Demografie, Gesundheit, Traumata und die Einstellung der Menschen zum Tod werden beleuchtet. Die Forschung zielt darauf ab, Ähnlichkeiten und Unterschiede zwischen den untersuchten neolithischen Siedlungen in dieser Region zu identifizieren und zu diskutieren, insbesondere im Hinblick auf paläodemografische Daten und die Anwendung von Gewalt. Mit Ausnahme einer kleinen Gruppe von Bestattungen in Aktopraklık, die im Gegensatz zu regelmäßigen Körperbestattungen standen, scheinen sich die Bestattungspraktiken kaum von einem Fundplatz zum nächsten zu unterscheiden und regionale Grenzen zu überspringen. Als Beispiel kann die Verwendung von Holzbrettern auf dem Boden von Grabgruben dienen, die erstmals in Ilıpınar entdeckt wurden. Die frühen Bauern der östlichen Marmararegion litten hauptsächlich an Gelenkerkrankungen und degenerativer Arthritis. Die Lebenserwartung lag bei Erwachsenen beiderlei Geschlechts zwischen 25 und 40 Jahren, wobei in zwei der vier Gemeinden eine hohe Kindersterblichkeit nachgewiesen werden konnte.

Schlüsselworte: Jungsteinzeit – Frühchalkolithikum, östliche Marmararegion, frühe bäuerliche Gemeinschaften, Archäologie, osteologische Analyse, Paläopathologie, Bestattungsbräuche, Gewalt

***Corresponding authors: M. Songül Alpaslan-Roodenberg**, Palaeo- and physical anthropologist – Department of Genetics, Harvard Medical School, 77 Avenue Louis Pasteur, Boston, MA 02115, USA. E-Mail: muyessersongul_alpaslan@hms.harvard.edu
Jacob Roodenberg, Archaeologist – Netherlands Institute for the Near East, Witte Singel 25, 2300 RA Leiden, The Netherlands. E-Mail: j.j.roodenberg@gmail.com

Résumé: A la suite de quelques décennies d'analyses ostéologiques cette étude présente une évaluation de données recueillies d'échantillons d'une population humaine provenant des premiers villages agricoles, à savoir Ilıpınar, Menteşe, Barcın et Aktopraklık, situés dans les bassins lacustres au sud-est de la mer de Marmara. Cette étude éclaircit plusieurs aspects de cette population comme les données démographiques, la santé, les traumatismes et l'attitude des anciens à l'égard de la mort. Les recherches ont pour but d'identifier et de discuter des similitudes et dissimilitudes entre les sites néolithiques étudiés dans cette région, surtout concernant les données paléo-démographiques et l'utilisation de la violence. A l'exception d'un petit groupe de sépultures à Aktopraklık qui contrastaient avec les inhumations traditionnelles, les pratiques mortuaires étaient à peine différentes d'une communauté à l'autre et dépassaient les frontières régionales. Un exemple peut être le plancher de bois couvrant le fond des fosses funéraires, dont l'utilisation fut découverte pour la première fois à Ilıpınar. Les premiers agriculteurs de la région orientale de la mer de Marmara souffraient avant tout de maladies articulaires et d'arthrite dégénérative. Leur espérance de vie était égale pour les adultes des deux sexes, entre 25 et 40 ans, tandis que deux des quatre communautés affichaient une mortalité infantile élevée.

Mots-clés: Néolithique – Chalcolithique ancien, région orientale de la mer de Marmara, villages d'agriculture précoce, archéologie, analyse ostéologique, paléopathologie, coutumes funéraires, violence

Abstract: Following on from a few decades of osteological analysis this study presents an assessment of the data retrieved from human population samples provided by four early farming sites, namely Ilıpınar, Menteşe, Barcın and Aktopraklık, located in the lake basins southeast of the Sea of Marmara. It highlights various aspects of that population such as demographic data, health, trauma, and ancient people's attitude toward death. The research aims to identify and discuss similarities and dissimilarities

Fig 1: Map with the Neolithic sites mentioned in the article.

between the studied Neolithic settlements in this region, especially with regard to paleo-demographic data and the use of violence. With exception of a small group of burials at Aktopraklık that contrasted with regular inhumations, it seems that mortuary practices barely differed from one community to another, and transcended across regional boundaries. The use of wooden planks covering the bottom of grave pits, which were first discovered at Ilıpınar, may serve as an example. Early farmers of the eastern Marmara region suffered mostly from joint diseases and degenerative arthritis. Their life expectancy was similar for adults of both sexes, at between 25–40 years, while two of the four communities showed high infant mortality.

Keywords: Neolithic – Early Chalcolithic, eastern Marmara region, early farming communities, archaeology, osteological analysis, palaeopathology, burial customs, violence

Introduction

This paper combines the data retrieved by osteological analysis of human remains uncovered at four Neolithic-Early Chalcolithic sites in the eastern Marmara region of northwest Anatolia to provide features regarding the contemporary population. Surveys of the region since the 1950's have identified a significant number of prehistoric monuments there, among them the sites of Ilıpınar near İznik Lake, Menteşe and Barcın in the plain of Yenişehir, and Aktopraklık in the vicinity of Uluabat (Apolyont) Lake, all located in lake basins of the lowlands southeast of the Sea of Marmara (fig. 1). The first three sites were examined in a research project entitled "Early farming communities in the eastern Marmara region" that was set up by the second writer on behalf of the Netherlands Institute for the Near East (NINO), Leiden/Holland, and its annex in Istanbul, the Netherlands Institute in Turkey (NIT), and involved in fieldwork seasons from 1987 till 2015. Excavations at Aktopraklık on behalf of the Prehistory Department of Istanbul University began 2004 and are on-going.

As the first farmers of the eastern Marmara region settled in the mid-7th millennium, at Barcın and Menteşe, and Ilıpınar and Aktopraklık were abandoned in the mid-6th millennium BCE, the population in this study belongs to a period of about one thousand years. The skeletal remains recovered from the four successively excavated and partially simultaneously inhabited early farming sites represents a total of 223 individuals. This is a fairly large number when compared to what is available from contemporary sites in adjacent areas such as western Anatolia and southeastern Europe.

The results of the analysis are presented in separate sections: 'archaeological context', 'material and method', 'mortuary practices', 'demography', 'health condition', 'injuries, violence and deviant burials', while an elaboration of the data is provided in the concluding 'discussion'. To highlight differences and similarities between the pop-

ulations of the four sites based on the above aspects, the article combines published and unpublished bio-archaeological data.

The archaeological context

Ilıpınar Höyük

The first prehistoric excavations of the eastern Marmara region began at Ilıpınar Höyük in 1987 as the lead-in to NINO/NIT's "The early farming communities research project". This site revealed in addition to the usual inventory of pottery and tools made of bone, horn and stone, a multitude of faunal and floral data demonstrating cultivation of a range of food plants and stockbreeding of cattle, sheep/goat and pig. Moreover, pedological conditions and destruction by fire allowed the preservation of wood used in different applications, not only in house building but also in graves. Due to the favorable preservation conditions the excavators were able in particular to provide a detailed picture of house constructions in the successive occupation layers[1].

A 400 sq.m. area in the center of the höyük immediately opposite the *pınar* (well) revealed the oldest deposit (6000–5900 cal BCE). This yielded the burials of 48 individuals, dug in spaces between the houses[2].

Menteşe

In the second half of the 1990's soundings carried out on this mound in the Yenişehir plain, 25 km northeast of the Iznik Lake basin, revealed the remains of an older settlement (6400–5800 cal BCE) where farmers cultivated foodplants and bred cattle and small ruminants. While the main purpose of these soundings was to confirm or otherwise the previously incomparable findings of Ilıpınar, in addition to the expected archaeological finds, the remains of 20 individuals were identified in the occupation layers[3].

Barcın Höyük

Systematic excavations at Barcın Höyük, situated in the same plain at Menteşe and designated as Yenişehir II in an earlier report[4], began in 2005 as the third objective of NINO/NIT's early farming research project, initially in collaboration with the Iznik Museum. These excavations revealed a farming settlement slightly older than the latter mentioned, establishing the onset of agriculture in the eastern Marmara region just before the mid 7th millennium[5]. Since 2007 the excavations have been transferred to NINO's annex NIT in Istanbul. Between 2005 and 2015, the remains of 72 individuals attributed to the Neolithic layers were uncovered in a relatively limited area with architectural remains. Preliminary reports on the human remains found between 2005 and 2012 have been published[6].

Aktopraklık

This large site on sloping terrain, and inhabited successively in the Late Neolithic (6400–6300 cal BCE) and the Early Chalcolithic period (after 6000), has yielded an abundant collection of human remains, in total from 83 individuals. It consists of several areas: A, B and C, the earliest graves being found in Aktopraklık C, today an olive grove, where a number of Neolithic skeletons were buried, some below hut floors. In the upper layers of the grove there were skeletons lying in flexed position, accompanied by burial gifts such as pots and personal ornaments. Together they constitute a graveyard dated around 5800–5600 and attributed to the Early Chalcolithic period[7]. In addition, the compact village of area B, dated ca. 6000–5800, yielded human remains buried in ditches and courtyards. Among them some burials drew attention because of the peculiar position of the deceased that was different from the common burial type in the Neolithic era of the region. In this study we call them 'deviant burials', a term that usually refers to the ritual character of such burials[8].

Materials and methods

Skeletal remains from 77 individuals excavated at Aktopraklık and Barcın were examined and included in this study. 146 of a total number of 223 Neolithic skeletons discussed in this paper were published earlier[9].

1 Coockson 2008; Roodenberg 2012.
2 Alpaslan-Roodenberg 2008.
3 Alpaslan-Roodenberg 2001.
4 French 1967.
5 Gerritsen/Özbal 2014.
6 Alpaslan-Roodenberg *et al.* 2013; Roodenberg *et al.* 2008.
7 Karul/Avcı 2013; Alpaslan-Roodenberg 2011a.
8 Murphy 2008.
9 Alpaslan-Roodenberg 2001; 2008; 2011a; Alpaslan-Roodenberg *et al.* 2013.

All skeletal remains collected during the investigation of the four sites were examined by the first author during the regular summer seasons. Insofar as Ilıpınar and Menteşe were concerned, it was possible to inspect each new grave in the field at the moment of discovery or shortly after and in many occasions the remains were cleaned by the first writer for further study, or directions were given on how to treat them. In archaeological practice the cleaning and removal of a skeleton is considered as a critical procedure, as it allows recording features of funerary and taphonomic importance that would be otherwise lost[10]. When collecting human remains with the proper care, significant details can be recorded *in situ* and the risk of overlooking small fragments, for instance infant teeth, can be avoided. Aktopraklık is also a good example in this respect, where the first writer was on-site when most of the skeletons were found and was able to personally supervise the cleaning and collection of the bones. When burials with unusually positioned individuals were discovered, she was consulted for advice on how to deal with these appropriately. As for the work at Barcın since 2007, by contrast, excavating and lifting human remains was apparently carried out according to a different standard. Fortunately, photographs from the excavation archive that were made available to her compensated to some extent to the loss of first-hand information regarding burial conditions.

The following methods were applied on the newly studied material.

Taphonomic changes such as weathering, discoloration, polish, cutmarks, rodent and carnivore gnawing, and the state of completeness of skeletal remains were recorded for each individual[11]. The most intact human remains of the eastern Marmara early farming villages were found in Menteşe where bones and dental remains were generally in a good state of preservation. This is partly due to the fact that the graves were retrieved from deeper levels. At Ilıpınar where the Neolithic graves were also in deeper levels, the skeletal parts were relatively well preserved as well, but a calcareous deposit often hindered cleaning the bones. This type of deposit occurred even more frequently at Aktopraklık owing to the high calcium content in the soil at which the site name hints – *ak toprak* meaning white soil. It was observed in particular on skeletons lying close to the surface as was the case in the Early Chalcolithic cemetery of area C. Moreover, these skeletons had suffered from later disturbances causing bones to fragment, and in some cases even disappear. Consequently, many individuals were missing various skeletal parts, although they still kept their original position in most graves and were in majority articulated, a strong indication of primary burial. Generally speaking, though, *postmortem* damage was seen at all sites but was particularly frequent in Aktopraklık C.

After removal of the entire skeleton or the surviving remains in a single operation the bones and teeth were routinely cleaned in the dig houses by using soft painting brushes. Depending of the degree of fragmentation and the preservation state of the material, careful cleaning with lukewarm water was sometimes needed.

Observations of bones and teeth were macroscopically performed as standard procedure, while some dental remains and pathological conditions were examined in detail with help of a compound light microscope (with 15x magnification). In all cases conventional osteological methods were applied to the study of the material, and the remains recorded in the appropriate skeletal and dental forms[12]. Any pathology, trauma details and non-metric traits were investigated and noted in tables[13]. Dental remains were examined individually and the following observations were marked on the appropriate dental form for adults and subadults: number of inspected teeth, antemortem loss, caries, alveolar atrophy, calculus, periodontal disease, congenitally tooth loss, additional tooth, task related changes in teeth, such as sulcus, dental wear and erosion[14].

Age, sex and stature were estimated according to the standard anthropological methods[15]. Cranial and postcranial measurements collected for each individual, when present[16]. Sex determination for adults was based on the morphology of the pelvis and skull respectively. Sex assessment of early adolescents by skeletal features remains in general an imprecise tool, and is even more so in the categories of infants and younger children. This is an area where genetic analysis will perhaps prove of great use in the future in the absence of any reliable osteological method to determine the sex of the subadults, although we should note that the accuracy of genetic sex determination is still debated[17].

10 Duday 2014, 7.
11 Buikstra/Ubelaker 1994.
12 Buikstra/Ubelaker 1994.
13 Steckel *et al.* 2006; Buikstra/Ubelaker 1994; Rotschild/Martin 1993.
14 Brothwell 1981.
15 Buikstra/Ubelaker 1994; Krogman/İşcan 1992; WEA 1980; Ubelaker 1978; Trotter/Gleser 1952; 1958.
16 Buikstra/Ubelaker 1994.
17 Skoglund *et al.* 2013.

Dental development stages, epiphyseal closure times and bone measurements were examined as an age indicator for infants and juveniles[18]. With regard to fetal remains, bone measurement was used to estimate age according to the methods of Fazekas and Kosa (1987). Assessment of age at death was more precise until adulthood which starts around 18 years, as is generally accepted. When there was no more than a few molar teeth left for probable age determination (of an adult), molar wear patterns were considered to assess the age. Following Brothwell (1981) adults were classified as young (18–25) middle-aged (25–35) and old (35–45 and older). Subadults are defined for this paper as infants between 0–2 years (prenatals between 32 and 38 weeks, neonatals between 38 and 40 weeks) juveniles 2–12 years, and adolescents 12–17/18 years.

Where present, age related skeletal changes were used as an age indicator in connection with other methods to assess the age of an adult skeleton.

Mortuary practices

As was usually the case with burials at early farming sites elsewhere in Anatolia those in the eastern Marmara regions were buried in a flexed position on their left or right side in a pit dug usually to a depth of slightly more than half a meter deep. There were a few exceptions to this rule, as seen at Aktopraklık and Barcın, that will be discussed in the section 'injuries, violence and deviant burials'. Generally speaking, the burials of the Neolithic and Early Chalcolithic period, in particularly those of the eastern Marmara region, of which the first author has examined practically the entire collection of human remains unearthed so far, are characterized by common features. These are:

- The graves contained usually one individual. In a few cases an infant was found in grave pits together with an adult or adolescent, Menteşe and Aktopraklık providing the best examples of this practice. However, the remains of two adults have been found in a single grave at Barcın and Aktopraklık, while multiple burials also were observed at Aktopraklık.
- The deceased were usually lying on their left or right side. Apparently, there was no obvious preference for one side or the other, although at Ilıpınar a slight preference was noted for adults to be buried on their right side[19]. The same is true for the overall orientation of the body indicated by the atlas – sacrum axis: no clear preference for certain points of the compass. Otherwise, at none of the sites examined was there an evident relationship between sex or age and the specific position of the skeletons.
- The dead were buried in a flexed posture, in which the legs were found more or less contracted towards the abdomen, and the arms bent so that the hands were lying close to the face or chest. Quite often the deceased had their arms and legs so tightly contracted as to suggest the body was firmly wrapped before it was lowered in the grave pit.
- Many graves included one or two ceramic vessels or an animal bone left next to the body. At Menteşe, and in particular at Aktopraklık, however, some contained more personal ornaments such as necklaces and bracelets. By contrast, the graves at Ilıpınar, as at Barcın contained fewer items, such as a single vessel, bone tool or animal bone. While the presence of personal items such as necklaces suggests in such cases that the dead were deliberately buried with their own belongings, the question remains open as to whether those other artefacts found in the graves were offerings to the deceased or leftovers from funeral meals.
- Where the graves of the Neolithic and Early Chalcolithic period we examined in the Marmara area initially seemed to differ from those in the wider region was in the use of wood. The first evidence for this was detected in some graves from Ilıpınar and Menteşe. One of the graves in Ilıpınar in which the wood was the best preserved, belongs to an old woman lying on a wooden plank (UAE, X13). The upper part of the skeleton was stained with a red-brown powdery substance, probably the remains of planks that had covered the corpse. The planks on which the deceased had been buried were of the same color and substance in which wood fibers were recognizable (fig. 2). At Menteşe, the grave of a young woman yielded pieces of wood that could be interpreted as the remains of a coffin[20], while at Barcın, the remains of a wooden planks were observed at the bottom of some graves. In two graves of Aktopraklık a reddish color was present on some bones, but whether this coloring was due to the application of ochre on the body or traces of decayed planks is uncertain.

18 Ubelaker 1978; Maresh 1970; Schaeffer *et al.* 2009.
19 Alpaslan-Roodenberg 2008.
20 Alpaslan-Roodenberg 2001.

Fig. 2: Old woman buried on a wooden plank (Ilıpınar, UAE, X13). The upper side of her bones was stained reddish-brown suggesting that her body was covered with planks as well.

One other feature of note was the evidence for various burial practices that came to light during the long excavation program at Aktopraklık's, where the mortuary record is different from the other villages. That is to say, Neolithic burials were sometimes underneath hut floors in area C, whereas burials of Early Chalcolithic date were found in ditches and a central courtyard examined in area B, with a range of other burials of the Early Chalcolithic cemetery in area C[21]. While the burials from the cemetery fit into the category of common graves of that period, the courtyard burials deviate from this in several ways as we shall see, described below in section 'Injuries, violence and deviant burials'.

Mass of stones and bones

Not less relevant to this section's theme of mortuary practices was the discovery at Aktopraklık of a grouping of isolated bones mixed with stones found in Area B. As excavated, this mass presented itself as an irregular accumulation of stones spread over an area of a few meters in diameter (fig. 3). The bones represented were for a large part dis-articulated leg and arm bones from different individuals and with no traces of any cut marks. In addition, there was a smaller number of skull, mandible and pelvis fragments and other parts. These dry adult bones, 71 pieces in total, all of which likely originated from old graves, subsequently stuck between the stones, while the long bones among them seemed to be placed in some form of order. The mass of stones also contained a small number of animal bones and pottery sherds clustered near the edge. Before collection for study the bone finds were cleaned *in situ*, numbered and marked on a photograph taken from the mass. Diagram 1 shows the human bone inventory recovered in this place, with 11 adults being the minimum number of individuals (MNI) recognized in the human remains on this spot. The MNI was estimated using the proximal left femurs[22]. Their details were added to the population of the successive occupation phases at Aktopraklık. We will never know for certain if any of these bones belonged to individuals from one or more of the disturbed regular graves previously studied, what would lead to double counting.

As far as is understood, stones had been piled one on another on this spot, with the bones from adults stuck in between. The pottery fragments and animal bones in the pile could represent the remnants of (ritual?) feasting, but without the archeozoological evidence of these animal bones as food debris that remains speculative. It is likely that the human skeletal parts had served a ritualistic purpose here, even though we are not aware of what that may have been. However, since the investigations at Aktopraklık have revealed a wide range of mortuary practices, one is not surprised to see evidence for some form of practice in which the inhabitants desecrated earlier graves to use their skeletal remains in a sort of ritual. These were dry, not anatomically connected bones, which confirms that they were by no means silent witnesses of human sacrifice on the spot. One may wonder whether the long bones between the stones displayed a pattern of some significance now lost for those who created this.

21 Karul 2018.

22 Ubelaker 2002.

Fig. 3: Accumulation of stones and bones unearthed at the edge of the central courtyard of the Early Chalcolithic settlement of Aktopraklık (area B).

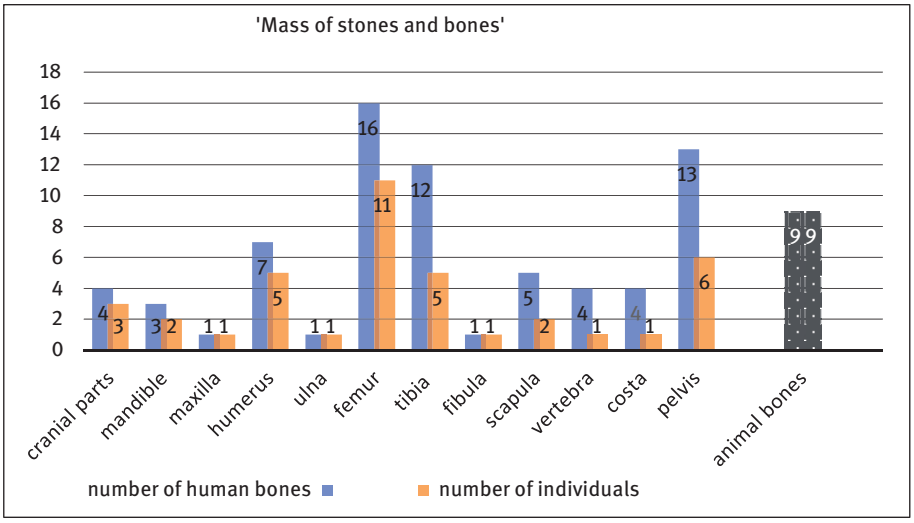

Diagram 1: Inventory of the mass of bones and stones found in Aktopraklık area B.The minimum-number of individuals being 11 was calculated by the left proximal femur part.

Biological sex and age at death (appendix: table 1)

In the four early farming villages discussed here skeletal remains of 223 individuals (92 subadults and 131 adults) were unearthed between 1990 and 2015. Not only their number but also the circumstances of their interment varied from site to site. Deep soundings at Menteşe yielded 18 single graves and one containing an older woman with a boy[23], roughly dated between 6400 to 6000 cal BCE, while in Barcın more than 70 were removed from a limited area covered with buildings and courtyards and dated to

23 Genetic sex determination, individual I0724/UP in Mathieson *et al.* 2015.

about the same time span[24]. The 48 deceased of Ilıpınar were equally exposed in courtyards within village ground but had been buried between ca. 6000 and 5850. The situation of Aktopraklık is more complicated given the spread of occupied areas and the longer period in which inhumation had taken place. A dozen Neolithic individuals were buried in Aktopraklık C and dated between 6300 and 6100, while the Early Chalcolithic individuals were found inhumated in the village surrounded by ditches (6000–5800) and in a cemetery (5800–5600) located in area C as well[25]. This leaves a theoretical span of eight centuries between interment of the earliest and last inhabitants of the latter site. However, as the number of individuals in each of the subsequent phases is not sufficient to identify discrete patterns with any degree of confidence, for our purposes all these individuals are grouped together for analysis.

The question of how representative population samples acquired from excavations relate to the entire village populations is not easy to answer. Since Ilıpınar and Barcın were small settlements, samples of respectively 48 and 72 individuals buried within a few hundred years can be considered representative with some caution[26]. This does not apply to Menteşe, since the limited sample was obtained from a restricted area of the Neolithic occupation of a site supposed to be of a size similar to Barcın and Ilıpınar. As for Aktopraklık, the settlement in area B would be eligible, if it were not that the number of graves is too small. Hence, the best suitable for demographic comparison are the population samples from Ilıpınar and Barcın.

Most striking is the resemblance in high infant mortality at both Ilıpınar and Barcın. When comparing subadults against adults, Barcın scores equally and Ilıpınar even scores two-third of subadults against one-third of adults. Keeping in mind how the results from Aktopraklık and especially Menteşe are less suitable for comparison, we observe a different picture: subadults at Aktopraklık still count for a quarter of the individuals, but instead of infants, juveniles represent the largest age category. We list below the demographic distribution of each site.

Ilıpınar

48 individuals (17 adults and 31 subadults, diagram 2a) from the oldest levels, 65 % of the population were subadults. Infants constituted almost half of the total population with 48 percent aged between 7–8 fetal months and 1,5 year old babies. Mortality declines strongly after infant age with 17 % juveniles between 3–9 years and disappears in the categories of adolescents and young adults. Females made 71 % of the total 17 adults, while 67 % of the adults died between 23 and 40 years. Despite this, the life expectancy of men and women was nearly equivalent[27].

Barcın

72 individuals, from which 37 adults and 35 subadults were identified (diagram 2b). The number of infants was strikingly high at 29 individuals, 40 % of the total individuals. Here also a decline in mortality is noticed from infant age onwards: a mere 17 % of subadults appeared to be juveniles (4) and adolescents (2), while young adults are nearly absent. Most infants died between 36 and 40 weeks prenatal during delivery or near birth.

A large number of infant bones and some adult skeletons found in 2014 and 15 could not be examined, and when the entire bone collection has been examined, the total number is likely to change in favor of infants. Otherwise of those examined, 62 % of all adults from which a sex assessment could be made were females (38 individuals: 18 females, 11 males and 9 undetermined), but most of them were 'probable' sex determinations in particular because of bad preservation and fragmentation of skeletal material. Life expectancy of males and females did not differ much. Most adults from both sexes died at middle to old age, between 25 and 45 years[28].

Aktopraklık

Many graves were uncovered in the settlement. The total number of the individuals examined here is 83 from which 2 infants, 11 juveniles, 4 adolescent and 66 adults were identified. This means that 80 % of the entire population were adults (diagram 2c). This percentage also includes 11 adults whose long bones were found in the mass of stones in area B discussed above, whereas the adults retrieved

24 Gerritsen/Özbal 2012.
25 Karul 2018.
26 48 and 72 are samples obtained from populations that, spread over several generations, may have included 400 to 600 individuals (margin of error 11 %; 90–95 % confidence level; spread unknown – for each characteristic – 50 %; source Corpos).
27 Alpaslan-Roodenberg 2008.
28 Alpaslan-Roodenberg *et al.* 2013.

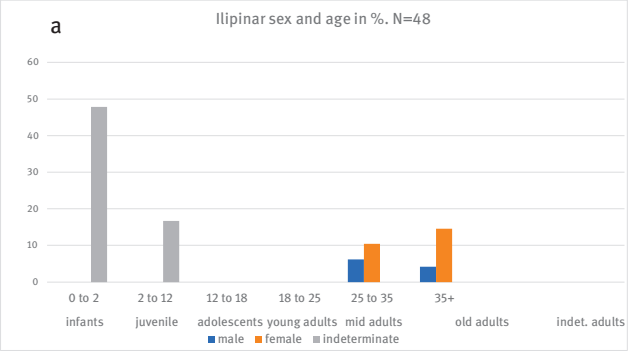

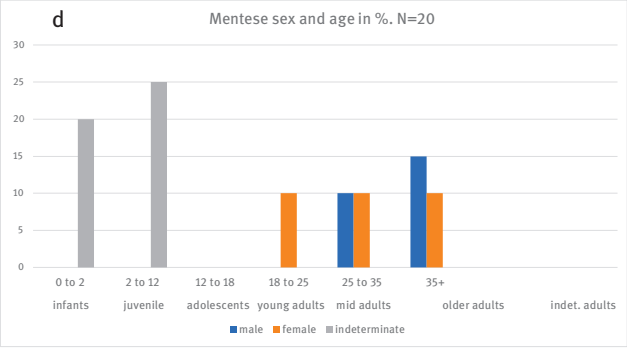

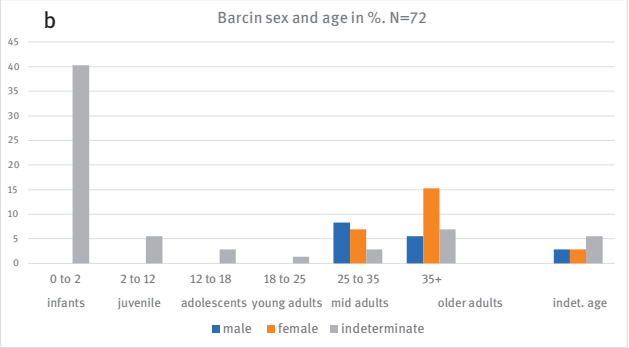

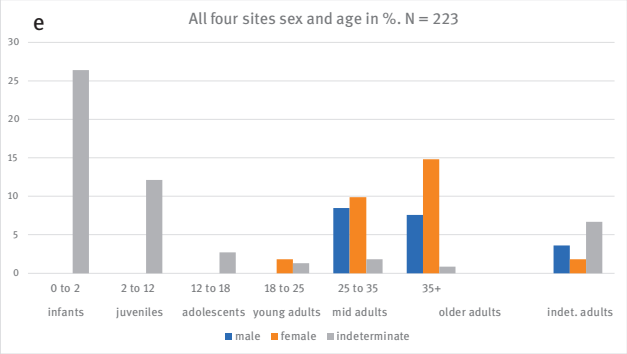

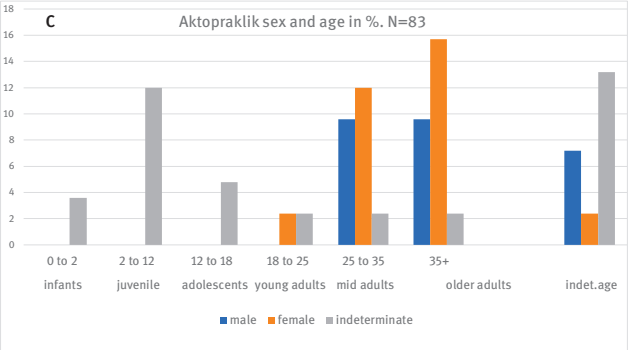

Diagram 2a–e: Sex and age distribution of the population samples from Ilıpınar, Barcın,Aktopraklık, and Menteşe, and from the four sites together.

from all graves and pits were 55 including 25 females, 22 males and 8 of undetermined sex. Although bones from 'probable male and female' were identified in the skeletal parts collection already mentioned, these are not included here in the sex and age determinations of the Aktopraklık population. Females seem to constitute the majority of the adults from which sex determination could be made.

Of these, among the 25 identified females 12 were young to middle-aged and 13 middle to old-aged. Males were little older than the females: 7 middle-aged, 6 of middle to old age, 2 of old age, between 40 and 70, and one of indeterminate age. The middle and older adult categories consisted in ascending scale of more males than females[29].

It is a peculiar aspect of Aktopraklık that almost no infant bones emerged during the 14 seasons of excavations. Remains of two infants were identified coincidentally: one found among animal bones and another close to a female grave. Given the huge presence of infant remains in the contemporary villages of the region, their almost complete absence here is puzzling, and it is possible that the sector where babies were interred will be detected one day. On the other hand, older children were not entirely absent: juveniles and adolescent constituted 18 percent of the population.

The demographic data from Menteşe is not really representative of the Neolithic village community, but the numbers are added up in the total population diagram below. The Menteşe sample counts 20 individuals including 11 adults, 9 subadults (diagram 2d). There were 4 infants between 0 and 9 months and 5 juveniles between

29 Alpaslan-Roodenberg 2011a.

2 and 12 years. Female and male adults in this sample are represented at an almost equal rate, respectively 6 and 5, while life expectancy was slightly in favor of males, 3 against 2 females[30].

When presenting all data provided by these 223 individuals buried at these four sites occupied between the mid-7th and the mid-6th millennia in a diagram, it is evident that the population of the eastern Marmara region is characterized by a high death rate among the youngest age groups: more than one-third of children died before the age of 12 (diagram 2e). Once puberty was reached, the mortality risk fell sharply and only rose again when people came to middle age (25 to 35). This applied to both men and women. The older adult category shows that in majority women reached an age above 35 years.

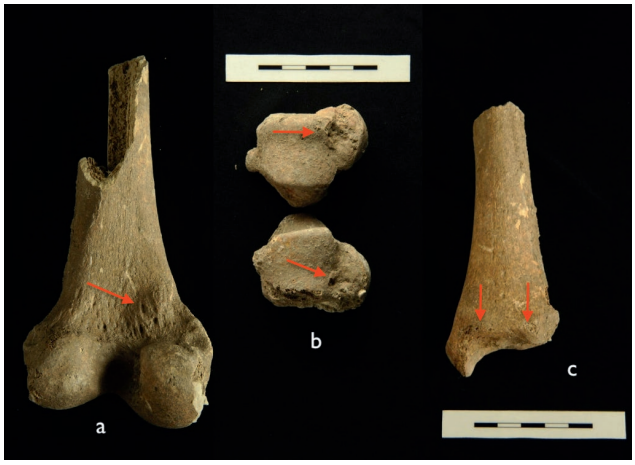

Fig. 4: Old female (90 E 13 2010) from Aktopraklık exhibits clear evidence of squatting in both her ankle and leg bones (see arrows). Fig. 4a shows a cortical defect in the posterior side of her right knee, 4b shows both ankle bones (talus) and 4c the left distal tibia.

Skeletal and oral health

This section largely deals with new data from 77 individuals found in Aktopraklık and Barcın collected from 2009 to 2015 (appendix: table 2).

Skeletal health at Aktopraklık

Pathological conditions were noticed in 14 from 18 examined adult skeletons (table 2).

Arthritic changes: 5 of 18 adults, mostly males, had osteoarthritic (OA) changes in their bones. The commonest finding was noticed in the spine as bony growths (marginal osteophytes) and surface porosity. The lumbar vertebrae, calcaneus and patella were the most frequently affected parts of the skeleton. Posterior calcaneal spur (enthesophytes of the achilles tendon) was also noted in the heel bones from both sexes, which is quite ordinary among elderly people[31].

Fusion of the sacroiliac joint by ossification of sacral ligaments due to a joint disease was observed on a small pelvis fragment from a middle to old-aged female (90E 16'10). The spine and right side of her pelvis were absent. Therefore, the differentiation of the disease which caused the ossification in her hip bone remained unknown. Diseases that can cause this condition are diffuse idiopatic skeletal hyperostosis (DISH), Forestier's disease, ankylosing spondylitis (AS) or degenerative osteophytosis[32].

Porosity was noted on the frontal part of a middle-aged male's skull (18L 58'11). Beside this his scapula also presented porosity. Pitting on the sternoclavicular joint surface of the left clavicle was observed as well. Osteoarthritis is a possible cause of these changes in his bones.

One middle-aged male (18L 58'11) had a mild lesion of periosteal reactions marked by longitudinal striations on the outer layer of the leg bone fragments (femur, tibia and fibula). This reaction can occur due to an injury or a medical condition. He had signs of osteoarthritis in his back, knee and foot.

The posterior side of the distal end of both femurs from an old female (90E 13'10) exhibited a cortical defect. It was more prominent at the left side than the right (fig. 4a) and was located above the medial condyle at the attachment of the medial head of the gastrocnemius muscle. According to general believe this is due to repeated pulling stress or acute trauma of the gastrocnemius muscle[33]. This old female also had squatting facets in both sides of the talus bone and distal tibia (fig. 4b, c). In the long term a sitting position can cause the cortical defect as described above. The gastrocnemius and soleus are the two muscles in the back of the calf. The gastrocnemius that starts above the knee inserts into the heel. The soleus muscle is on the back of the tibia, the lower leg bone that inserts onto the heel. When someone squats, the knee will be bent and this will put stress on the gastrocnemius muscle.

The foramen mentale (MF) in the left side of the lower jaw from a middle-aged female (88F 13'09) appeared to

30 Alpaslan-Roodenberg 2001.
31 Mann/Murphy 1990.
32 Roberts/Manchester 1995.
33 Mann/Murphy 1990.

Fig. 5a: Enlarged foramen mentale in the left side of a mandible from a middle-aged female (88 F 13, 2009, Aktopraklık). The foramen mentale in the right side of the same jaw kept its normal size.
b) Edentulous mandible fragment of an old man (88 F 15.1 2009, Aktopraklık). The circle indicates a large depression at the posterior left side of the ramus.

be much larger than the one in the right side. The latter of these openings giving path to vessels and the mental nerve had a normal size. There were vertical and horizontal cracks in the jaw bone around the foramen in the left side. The oval shaped size of this foramen measured vertically 7.07 mm and horizontally 7.69 mm, which is 2–3 times larger than the usual size of foramina (fig. 5a). On both sides of the jaw the foramen was located on a longitudinal axis passing between the first and second premolars being one of the most common positions of MF in relation to teeth of the lower jaw[34]. The teeth around MF did not show dental disease such as caries or abscesses, although the rest of the canal should be examined radiographically to see whether it was also affected.

Another observation of the same female (88F 13'09) revealed an osteoma around her right external ear canal. This is a common benign bone tumor of the external auditory canal. It is believed to be the result of chronic irritation of the ear canal (physical, chemical or thermal) and may cause mild to severe chronic pain. In the pre-antibiotic era this defect was frequently seen secondary to chronic infections[35].

Fragmentarily preserved skeleton 88F 15.1'09, presumably male because of the rather robust bones, had a bone atrophy on an edentulous mandible fragment. Exact age determination was not possible because many bone parts were fragmentary or missing. All his mandibular molars were lost antemortem, while 5 of the 8 remaining isolated mandibular front teeth exhibited caries. As a result of ageing the bone had become thinner and greatly reduced in size. Beside this a large depression was found at the ramus mandibula level (fig. 5b).

The skeletal material from Aktopraklık exhibited the following non-metric traits.

A bipartite patella in the superolateral (upper, outer) portion of the right kneecap of a middle-aged female (89F21'09). The patella is made up of two distinct bones. This condition occurs when the fusion of them fails during childhood. In our case these pieces were partly fused. The apex of the patella was missing.

A vastus notch, a small notch on the superolateral margin of the patella[36] was found in 2 individuals: the left patella of an adolescent (19K 37.1'10), and both patellae in a middle-aged male (18L58'11). The middle-aged man also had a vastus fossa (facet or a small depression) along the superolateral margin of his knee caps.

The isolated skull of a middle-aged male (19M 7.1'10), found in a cluster of stones (fig. 6a), presented a metopic suture and wormian bones on both the right and left side of his occipital bone. The frontal bones were separated by a persistent metopic suture between nasion and bregma, a condition called metopism. Metopic suture disappears around the age of 8, but it remains persistent in 9 percent of the cases[37]. Apart from this, there were many irregularly shaped sutural bones at the right and left lambdoid sutures called wormian bones. The occurrence of both conditions in one skull is rare in the literature.

An old female (90E 13'10) and a middle-aged male (19K 35.1'10) presented squatting facets in their lower legs and foot bones. The male had them on his right talus

34 Budhiraja *et al.* 2013.

35 Turetsky/Vines/Clayman 1990.
36 White *et al.* 2012.
37 Ambade *et al.* 2017.

Fig. 6a: Skull (19M 7.1 2010) uncovered among stones in the Early Chalcolithic settlement of Aktopraklık B.

fig. 6b: Cut marks on top of the skull in fig. 6a are indicated by arrows.

and right tibia, the female in both her left and right ankle bones (fig. 4).

A septal aperture was observed in the left side humerus of a middle to old-aged female (88D 106'10) and a male of unknown age (89F 20.1'10) also had this feature in his right side humerus, while his left humerus was missing. This is a common anatomic variant in human distal humeri that is thought to occur in childhood[38].

In the right and left sides of the upper part of the brow ridge above the eye socket of an old male (88F 15.1'10) the supra orbital foramen was noticed. This is a small groove in which pass the supraorbital vessels and nerve.

Skeletal health at Barcın

Pathological features were present in 15 of 19 adults.

Skeletal remains of 13 of 19 adult individuals exhibited arthritic changes: 4 females and 4 males of the ones whose sex could be determined. They were all middle and old-aged individuals and it seems that arthritis affected both sexes equally. Spinal osteophytosis and osteophytes in hand phalanges were found in majority on individuals of both sexes who were affected by osteoarthritis due to increasing age. Older age is the greatest risk factor for osteoarthritis, osteophytes being common in aged populations[39].

A female (M13 171) aged between 20 and 35 had fused thoracic vertebrae. At least two of the vertebrae were affected, which signals a form of degenerative arthritis. She also developed ligament ossification in her left distal tibia called "posterior inferior tibiofibular ligament ossification" (fig. 7). Tibiofibular syndesmosis and ossification occurred most likely because of an ankle sprain causing mild to severe chronic pain. In the same leg she had two more injuries that were obviously made by sharp, pointed objects (see 'Injuries, violence and deviant burials'; fig. 8a, b). It is very likely that the fused vertebrae in her lower back gave her pain and may have limited her movements, while persistent ankle pain made it difficult for her to walk.

A middle-aged male (L10 E 173) presented a Schmorl's nodule in his first three lumbar vertebrae. This feature is related to great pressure exerted on the spine, which probably indicates that he was used to carrying heavy loads.

Ligament ossification was detected in the right calcaneus of a middle-aged female (M11 S 345). The dorsal calcaneocuboid ligament was ossified plausibly as a consequence of arthritis (fig. 9a). She had also another problem in the same foot: an excessive form of a calcaneal spur (fig. 9b). A great bone mass had grown under her right heel presumably causing much pain when she walked.

Porotic hyperostosis and cribra orbitalia were detected in the cranial vault and orbital roof respectively in 8 of the 19 adults from Barcın. These conditions are known to be associated with anemia due to an iron deficient diet, malnutrition and infectious disease. Porotic lesions in the cranial vault affected 3 males and 4 females demonstrating that individuals of both sexes were suffering from this. Cribra orbitalia was found in two females and one male showing both cribra orbitalia and porotic hyperosto-

38 Sahajpal/Pichora 2006.

39 Anderson/Loeser 2010.

Fig. 7: A middle-aged woman from Barcın (M13 171) developed ligament ossification in her left distal tibia (see arrow).



Fig. 8: The right knee of middle-aged woman M13 171 from Barcın exhibited several injuries: a relatively small cut mark in the side of the medial condyle (b) and a larger and longer cut mark in the anterior surface of the distal femur from the medial side of the leg (a). Apparently, a sharp pointed object was pierced into the bone until the beginning of intercondylar fossa (arrows). The objects causing the injuries were not left in the wounds. There were no healing marks.

sis, while the entire skull of one female (M11 S 343.2) bore many porotic lesions.

Two middle to old-aged females (M11-S 401 and M11-S 345) had developed squatting facets on the ankle bones. As remarked above with regard to Aktopraklık, habitual squatting causes modifications called squatting facets on the neck of the talus and distal tibia in response to strong pressure on ankle bones. Both women presented this pattern in their right side ankle bones; the ankle bones from the left side were not preserved.

Non metric variations among the Barcın population included a vastus notch noticed on kneecaps of two individuals, in the left patella of an older female (M11 S 40) and in the right patella of a middle-aged male (M13 119). Also, septal aperture occurred in the distal portion of both humeri of a middle-aged male (L10 E 126.1).

Oral health at Aktopraklık

Dental problems were present in 14 of 18 adults, with antemortem tooth loss, caries and abscesses, degree of alveolar atrophy, calculus formation, periodontitis, congenital tooth loss, additional tooth and sulcus like features recorded in the population. Caries was noted in two adults (middle-aged female 88F 13’09 and middle to old-aged female 19I 97’13) where it affected premolar and molar teeth. Five adults had lost several premolars and molars antemortem. An old male (88F 15.1’09) lost all mandibular molars antemortem and had one carious tooth left in his jaw.

One middle to old female (19I 97’13) had lost antemortem 3 teeth (molar and premolars), and a middle-aged male (18L 58’11) missed 3 teeth antemortem (molar and premolars) while another (19K 35.1’10), had lost one premolar tooth antemortem.

Three adults presented a moderate to advanced degree of alveolar atrophy, but no periodontal disease was detected among the individuals examined. A middle-aged female (89F 21.1’09) had an additional tooth in her upper jaw on the left side between the canine and the first premolar. A child aged between 3 and 3,5 years (19K 33.3. 2010) had a congenitally missing tooth (lower central right milk incisor) and the second milk incisor of the child was enlarged in the shape of a cone.

A middle-aged female (88F 13’09) exhibited a sulcus like feature in her right canine and premolar teeth from both upper and lower jaws. While the canines were worn buccolingually, the premolars were worn mesiodistally.

The subadults at the site displayed no dental pathologies, although two juveniles presented wear pattern on their milk teeth with heavy dentine exposure.

Fig. 9a: Ossification of the dorsal calcaneocuboid ligament due to probable arthritis in middle-aged female M11 S 345, Barcın. b) Large bone mass under the right foot of the same female.

Oral health at Barcın

Dental remains from 18 of 19 adults exhibited the following diseases: antemortem tooth loss, caries and abscesses, degree of alveolar atrophy, calculus formation, periodontitis, congenital tooth loss. No pathological condition was observed in teeth from subadults. Five of the 18 adults showed carious teeth, among them a middle-aged female and an old male. Two old individuals of indeterminate sex had many carious teeth (appendix: table 2, dental pathology), while 4 mid-old people exhibited antemortem tooth loss. One of them was a female who had also a carious tooth in her mouth. The degree of alveolar atrophy was moderate in most adults, whereas atrophy was advanced in older adults as expected. The majority (11) had a slight to moderate level of calculus. Advanced calculus formation was noted in a middle to old-aged male and an older adult of unknown sex. Although sample size is small, it is curious that a moderate level of calculus occurred in females (4 females, one unknown sex) and a slight level only in males (5 individuals). Incidentally, no relationship could be demonstrated between their age and the level of calculus formation in their mouth. Periodontal disease was found in two cases: a slight level of periodontitis in a middle-aged male, and a moderate level in an adult of indeterminate sex and age. Congenital missing teeth were recorded in 3 adults: 2 males had one congenital missing tooth and one female two. In all cases these were mandibular third molars from both sides.

Injuries, violence and deviant burials

Evidence of injuries and traumas will be discussed in two categories: fractures that occur in everyday life and fractures and traumas as a consequence of bodily violence. The first category was represented in the buried populations of all four sites in the Eastern Marmara region. The second usually concerns serious injuries that impacted on the bones. In addition, there is a group of skeletons different from ordinary burials, whose atypical burial positions point to the use of force to make them end up in the grave pits. The latter group described under the heading 'violence and deviant burials' was met in Aktopraklık, but Barcın also yielded two cases of deviant burials (table 2).

Burials at Barcın

Among the skeletal remains two were particularly noticeable due to traces of bone injury. The first was that of a woman aged between 25 and 35 years (M11-S. 345) who was found lying next to a wooden plank (fig. 10). As already noted, wooden planking has been discovered in three of the four villages where it was used to cover the base of grave pits. The plank in this burial seems also connected with the deceased. Very likely it had been used as a bier and when her body was laid in the pit, it was placed next to the body. The body position in the grave was also unusual. Instead of lying on her side in a flexed position, she was laid on her back, with her legs pulled up tight against the abdomen, arms folded crosswise over her chest, with a metapodium fragment of a large animal placed on her chest.

The remains of this women displayed several pathological features indicating peri-mortem trauma. For example, the pointed end of a bone tool remained *in situ* in her third lumbar vertebra (fig. 11a, b), and another was detected in her hip. Most striking was the head with its first three neck vertebrae still articulated to the skull. The head was severed from the body and placed on the chest again in the opposite direction of its anatomical position (fig. 10). The injury displayed in the third lumbar vertebra would have damaged the abdominal aorta that runs down there and consequently caused a great deal of blood loss, and so probably caused her death, especially as there was no sign of healing around the wound. Perforations were observed in two wrist bones. Her arms were crossed over each other and hands were on each side of her abdomen. The biggest perforation was found in the middle of the left wrist (fig. 11c).

Fig. 10: Grave of beheaded female M11-S. 345(Barcın), aged between 25 and 35 years old who was found lying on her back next to wooden planks (arrow).On her chest lay originally a cattle metapodium (removed before the picture was taken).

A second female who had obvious traces of trauma in her postcranial skeleton was between 20 and 35 years old (M13–171 2013). She was buried in the traditional way, a flexed position on her left side. Her left arm crossed her chest, her right hand rested on her right knee, as suggested by some hand phalanxes found on her distal femur part. Near her left upper arm was an animal bone. There was clear evidence for several injuries in the left leg, obviously made by sharp, pointed objects. The following injuries may represent the malicious wounding of this individual. A deep oblique wound in the right femur suggested that a pointed instrument was stuck until the knee from the inner side of the leg. Another, smaller incision was noticed in the same leg on the medial epicondyle (table 2: trauma, injury; fig. 8a,b). Both wounds remained unhealed, which shows that they did not occur long before her death. Whether these were fatal injuries is not clear, but she did not survive these for long.

Burials at Aktopraklık

A group of burials uncovered in the Early Chalcolithic village is discussed here in this category. Because of the unusual skeletal positions they differ from the others found in the settlement. They include 8 individuals found in 6 pits clustered in a centrally situated courtyard of the Chalcolithic settlement (area B, squares 18K, 19 K and 19M). Two children were buried separately in single grave pits (19K 67 2011 and 19K 40 2010) and two others with an adult and a late adolescent respectively (19K 35.1 and 35.2 2010; 19K 37.1 and 19K 33.3 2010). Another adult was buried in prone position on his face (18L 58 2011), and a skull without postcranial remains of yet another adult male was found in a stones cluster (19M 7.1 2010).

The following clues point to the brutal treatment of these people:

- Some skeletons carry unmistakable traces of assault resulting in death. Apart from that there were many old (cranial) breaks, but this kind of fractures may also occur through post-depositional processes.
- Skeletal positions in the pits deviated from the usual flexed posture of regular inhumations suggesting in some cases that individuals were possibly buried alive, while in others they were dead before they ended up in the grave.

19K 67 2011 (juvenile)

This child aged ca. 7 years was found in a sitting position with the left hand resting on the lap. The right leg was extended while an upper leg bone found in the pelvic area suggests that the left leg was pulled up into the abdomen, an empty space left in the pit, after it was filled allowing the lower leg bones to fall on the bottom (fig. 12). Except for the child's strange position, there was no evidence on the bones for violence.



Fig. 11a: The beheaded female had an injury in her third lumbar vertebra that was probably fatal. Fragments of the bone point were still in the wound. b) The wound after the bone tool was removed. c) One of her pierced wrist bones (left os capitate).

Fig. 12: Child buried in sitting position (19K 67, 2011, Aktopraklık).

Fig. 13: Male fallen on his face (18L 58 2011, Aktopraklık).

18L 58 2011 (adult)

A man with very robust bones was found buried on his face, his position indicating he had fallen forward when kneeling on the bottom of the pit, his arms being stretched out in front of him, the right one still visible to the right, the left one under the body (fig. 13).

Fig. 14: Fractures in the skull of a male (18L 58 2011, Aktopraklık). The incision made by a sharp object is shown by arrows.

The skull bones showed several linear fractures. Parallel to the sagittal suture ran a 15 to 16 cm long sharply edged incision (fig. 14). Obviously he was injured with a sharp instrument at the back of the head. The other fractures must have occurred after the death.

The following pathological conditions were observed. His right knee (medial margin of the left patella) exhibited a healed injury, and the right fibula's lower end had a long vertical cut mark on the lateral side. Since the right fibula was broken in two pieces and the broken fragment was missing, this cut mark could be measured until its broken end. It appears that the bone was cut with a sharp object. No healing marks were noticed (table 2).

19M 7.1- 2011 (skull)

An almost complete human skull was discovered lying on its left side among a heap of stones (fig. 6a). The right side was cracked and fragments were inside the skull. From the mandible a left fragment with 4 teeth was also preserved. Other than half of the first cervical vertebra (atlas) no postcranial bones were present. This vertebra fragment was still attached to the base of the skull suggesting at least that the skull had been removed when the corps was not yet in an advanced state of decomposition. Whether the individual was alive or dead when the skull was removed is difficult to establish, but the head area was surely still fleshy as cut marks on both parietal and frontal bones indicate the removal of soft tissue, variations in size implying the skull was cleaned with different cutting tools (fig. 6b). All skull features point to a male whose age must be assessed from young to middle on the basis of the tooth wear pattern and the cranial sutures. Metopic suture and wormian bones were both present.

Fig. 15: A 3–3,5 years old child buried on the back with the hands tied behind the back (19K 40 2010).

Fig. 16: The left side of the skull of the child (19K 40 2010) presented a small notch (arrow).

19K 40. 2010 (juvenile)

This child skeleton was found on the back, head facing upwards and right arm turned behind (fig. 15). The position of the left arm was less clear, but from the place of the leg bones it is possible to imagine that the child was kneeling, hands tied on the back, and once dead had fallen backwards. On the left side of the skull there was a small notch 6–8 mm wide, probably a trace left from a tool (fig. 16). There were many fractures on the skull, but they may be the result of *postmortem* conditions. The child was 3 to 3,5 years old.

Fig. 17: A middle-aged male (19K 35.1) and a 3–3,5 years old child (19K 35.2) buried together in a pit. Note their strange positions, for example the feet of the male (see arrows).

19K. 35.1 (adult) 35.2 (juvenile) 2010

This grave included the skeletons of an adult and a child. The adult had robust bones and the skull and pelvic bones had strong male features, also his stature was comparable to the other males in the village. This skeleton has been identified as a genetic female according to DNA analysis (Hofmanova, 2016:p.177: Akt 62: 19K 35.1), but as the child and the adult male remains share the same burial number, 19K 35, it is possible that the child (19K 35.2; lab No. Akt 61) and the adult male (19K 35.1) samples were mixed before analysis. Partly leaning with his right side against the pit wall he was standing on the toes of his right foot, while his left foot touched the earthen wall as if he tried to climb. The position of his arms suggests that his hands were tied in front of his abdomen. He held his head backward, his face up. Was he buried alive? Judging from its position the

Fig. 18: An adolescent and a child ca 3–3,5 year old were found in the same pit (19 K 37.1 and 19 K 33.3, 2010) in the central courtyard of the Aktopraklık area B settlement. They were buried face to face in sitting position.

child next to him seemed already dead when it ended up in the pit, because the body was partly hidden under the male skeleton, the legs lying straight forward and the head tilted to one side (fig. 17).

19K 37.1 (adolescent) and 33.3 (juvenile) 2010

In the adjacent grave there were also skeletons of two individuals: an adolescent aged 15–17 and a child of 3–3,5 years (fig. 18). The adolescent was sitting with spread legs, arms folded behind the back, hands probably tied, the head held back and the face turned up. The child was also found in sitting position, half way between the adolescent's knees, suggesting that they were face to face when alive. Once dead, the child's body had fallen over, while the adolescent had fallen back. The latter possessed pronounced female like skull features. Considering this and the rather tall stature, this individual can have been a young male or a tall female. He/she had rather long forearms comparing to the upper arms. As a consequence, stature estimation based on the length of the forearm bones turned out 10 cm higher than the one based on the length of the upper arm bones. Some postcranial bones had porosity (femur, proximal neck).

The child's first upper milk molars from both sides exhibited a clear red color on their occlusal surfaces, suggesting some reddish substance, a piece of rope or textile, had been inserted between the teeth and in front of the mouth (fig. 19a). Was the child muzzled? The child's left parietal also had a chop mark similar to that of the child of the same age in the single grave 19K 40. The width of this notch measured equally 6–8 mm (fig. 19b). No pathology

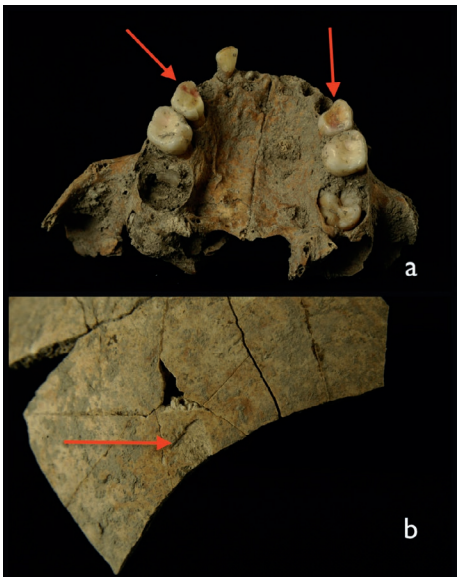

Fig. 19a: One of the children found in 19 K together with an adolescent had a reddish colouring on the surface of the front teeth (19K 33.3). At the level of upper jaw's right and left milk molars.
b) child's left parietal presented a chop mark (19K 33.3). It is similar to the notch found in another same age child's head in the same square (19K 40).

Fig. 20: A headless child skeleton in flexed position was unearthed in the Aktopraklik area B settlement (18K 27.2 2015).

was observed in the skeleton, except that one of the lower milk incisors was missing congenitally (LR milk incisor).

18K 27.2. 2015 (juvenile)

This burial, that of a ca. 11 years old child found in a flexed position on its left side, and located in the central courtyard of the area B settlement was remarkable in being headless (fig. 20). Above the grave was a level with architectural remains, and so it may be linked with the dwellings above.

Discussion

The collection of skeletons unearthed in the four early farming villages of the eastern Marmara region, Ilıpınar, Menteşe, Barcın, and Aktopraklık constitute a precious source of human remains from this period. With a total number of 223 individuals involving 92 subadults and 131 adults it is one of the largest human bone collections compared with early farming sites in the eastern Balkans and western Anatolia. These eastern Marmara early farmers buried their dead in pits generally dug in courtyards, although inhumation underneath dwelling floors occurred. In most cases the graves contained remains of a single primarily buried individual lying in flexed position on the right or left side, although double burials were found in all four sites. In addition to this relatively 'standard' method of inhumation, though, the Early Chalcolithic settlement of Aktopraklık B produced an area where human bones stuck between a heap of stones, and also skeletons of individuals buried in highly unusual ways.

Life expectancy in the four communities was similar for adults of both sexes, at between 25–40 years. As for the youngest age category, Ilıpınar yielded striking numbers of infant burials, and although this study does not include all infant burials discovered at Barcın, the indications are for a high mortality rate among neonates in this village as well. If they had survived, the majority had a chance to reach adulthood as juvenile remains show a significant decrease in mortality and adolescent graves were rare. Unfortunately, Menteşe produced too few remains to be of any statistical significance, but it is noteworthy that while Ilıpınar and Barcın provided substantial numbers of infant skeletons, almost none were discovered in Aktopraklık. High mortality percentages among infants such as at Ilıpınar and Barcın are rather the rule than the exception, because infant mortality continued to be almost consistently high in that area until sub recently[40]. It is unlikely

40 Göksu/Timms 1999.

that the infant population of Aktopraklık did not conform to this rule, and so it may be assumed that babies were buried in a section of the site that has not been excavated.

Aktopraklık is distinctive in more aspects from the other villages. For example, graves contained large numbers of artefacts[41]. Although limited in number, the Menteşe graves were also relatively rich in this respect when compared to those at Ilıpınar and Barcın. Among other finds found in regular graves of the Early Chalcolithic burial yard at Aktopraklık, many adults and adolescents were buried with a variety of necklaces and bracelets; sometimes more than 200 small beads were found in one grave. Pottery was another abundant component of these graves, which sometimes contained up to 5 or 6 vessels, demonstrating the importance that the inhabitants gave to funeral customs and perhaps also indicating the prosperity of the village. A missing element in the graves from Aktopraklık was wooden planks on the bottoms. In some cases, brown or red stains were observed on skeletons, but whether this resulted from contact with wood cannot be confirmed. This in contrast to the other three sites where a number of grave bottoms evidenced this practice.

As it is, wooden planks have been identified sometimes on the bottom of grave pits in other sites around the Marmara Sea such as recent findings in Yenikapı, Istanbul, indicating that the use of wooden biers or even coffins as part of the funerary ceremony was prevalent along the shores of the Marmara Sea[42]. We do not know why the employment of planks in graves was restricted to certain members of the population only. The evidence from Ilıpınar however suggests that this mortuary practice was not sex or age-related, and so depended probably from the status of individuals or families in the community.

Aktopraklık stands alone from the other sites with regard to the mortuary related acts identified there. For example, the accumulation of stones and isolated bones in a small area of the Early Chalcolithic village (area B). Dominant here were unarticulated bones belonging to a minimum of 11 adults. Examination of these bones did not provide any clues for trauma such as cut or chop marks, and it is clear that the skeletal parts brought to this place when dry, indicating they were sourced from long dead individuals. If these bones had played a role in some ritual, it is assumed they were retrieved from old graves. At the edge of this mass of stones and bones fragmentary animal bones and small pottery fragments were found, but whether these items were part of a ceremonial happening in which human bones had a function is uncertain.

Special attention is drawn by a small group of burials, also from Aktopraklık, contrasting strongly with the regular burials uncovered in the cemetery of area C, which is so far the only cemetery of that early period discovered in the wider region.[43] Although there was no clear bone evidence of violence, the unusual positions of these individuals suggest that they may have been subjected to brutal force about the time of their burial. To begin with, the pits containing these skeletons were deeper than the ordinary graves and were restricted to an otherwise empty area, in the center of the Early Chalcolithic settlement, area B[44]. Secondly, a number of them had their hands tied, as it seems. Moreover, while the children found here were most likely not alive when their corpse was lowered in the pits, the adolescent and adult looked upwards with open mouths, although the fact that they were found with their mouths wide open may result from the *postmortem* lowering of the mandible. The circumstances that might lie behind these atypical inhumations is difficult to pin down, and the presence of children in these pits is certainly confusing whichever way one wants to interpret these 'burials'. Yet it is difficult to ignore the impression that these burials represent some form of deliberate liquidations of those concerned. Perhaps the red paint found on the front teeth (mouth) of one of the dead children provides a clue for ritual acts in which these seven people were involved.

Aktopraklık also provided a single skull of a middle-aged male buried in the Chalcolithic settlement on a pile of stones and which bore many cut marks, obviously the result of de-fleshing. The presence of the mandible and a piece of the neck vertebra at its base indicates that the skull was possibly severed from a corpse rather than retrieved from a skeleton in dry condition. Another case was that of a child buried in what was otherwise a regular form of grave but headless. It is difficult to find a plausible explanation for the combination of a headless corpse and a traditional inhumation, that is to say, the body laid to rest in flexed position.

From the above it can be assumed that the population at Aktopraklık was accustomed to violence in one form

41 Karul 2018, 152 ff.
42 Kızıltan/Polat 2013.
43 From occupation areas of contemporary villages in NW Anatolia, such as Ilıpınar VIII–VI (ca. 5800–5600 cal BCE), graves are unknown so far. This absence of human remains at these sites has already given rise to speculation about the existence of separate cemeteries from a time shortly after the beginning of the VIth millennium (Roodenberg 2019).
44 Karul 2018, 152.

or another. Certainly the people there were not immune from experiencing violent death as is demonstrated by the skeleton of the middle-aged male of the same site. This man had received a lethal blow by a flint arrow head in his abdomen, a probable case of homicide; yet he was buried in a traditional way[45]. The Barcın population likewise displayed evidence for the use of brutal force. Two female skeletons were found with cut marks. One of them was dangerously injured, as shown by the point of a large bone tool that had penetrated the third lumbar vertebra and probably caused her death. Her severed skull lay between her shoulders.

Such evidence for violence against individuals amongst the early farming communities of the Marmara Sea area, as seen at Aktopraklık and Barcın, can be observed at other sites of the same period in the wider region. The first author's analysis of the human remains from Yabalkovo in Bulgarian Upper Thrace, a settlement occupied in the first centuries of the sixth millennium, also yielded a few individuals who had died in an unnatural way[46]. As for decapitation, the practice is known from early societies in the Levant, southeast and central Anatolia and many have tried to explain this phenomenon[47]. However, its significance in cultural anthropology is considered complex and ambiguous[48], and so it is not useful to speculate in this study on the few cases that were recorded.

Marks of violence and trauma that could easily result from everyday life were noticed among the remains from inhabitants of Ilıpınar and Menteşe. For example, head injuries caused by sharp instruments were observed in two adult males at Ilıpınar, who were non-fatally injured by a sharp object on one side of their head, while at Menteşe two adults had several fractures (mechanical traumas), and a young female showed a healed impression fracture of the cranial vault (right parietal) and a split and fused distal phalanx of one of her thumbs. The skeleton of a middle-aged male from the same site had a healed fracture of the right clavicle, and the left forearm of another middle-aged male had been broken and subsequently healed[49]. Daily life traumas were likewise represented in 11 percent of the adults examined from Aktopraklık, including healed fractures, mainly of long bones, as well as a 25 to 35 years old female who had received a blow on her shoulder causing a broken collarbone. In addition, there was a male with cut marks on the left side of his head made by a sharp instrument, his left elbow having been broken also and subsequently healed, while an old male had an injury to his right lower leg. Finally, an old female from Barcın had suffered from a fracture of her left forearm that had not properly healed. From the above it is evident that the number of people who suffered injuries during their lifetime was quite substantial among the 223 individuals examined.

With regard to diseases and ailments, in what was a short life compared to modern populations, the early farmers of the eastern Marmara suffered mostly from joint diseases and degenerative arthritis (OA). These problems most likely occurred through both ageing and a lifestyle that involved sustained and repetitive workload as part of daily routine, men in particular carrying heavy burdens, while at Aktopraklık and Barcın, some people presented squatting facets in their ankle bones. The presence of this facet showed that these individuals, all females except one, habitually assumed a squatting posture, a position commonly adopted in grinding flour and other products[50]. The women at all four sites were evidently also involved in another if lighter yet sustained working practice, as shown by a specific wear type in the front teeth of the females in the relevant populations. These were tooth wear marks in the form of sulci or grooves seen in a relatively large number of females, and which most probably developed when threads containing silicate were thinned by the front teeth on a recurrent basis by these females. We believe these resulted from tasks mostly done by women, such as weaving and basketry making. It seems that this tradition was common in early farming settlements in the Levant and Anatolia[51]. As it is, Ilıpınar provided examples of females lacking such grooves, but in these cases the women had a dental problem or a skeletal disorder, which made it probably difficult to use their teeth for such work (ibid., 2008). All in all, then, the remains from the four sites provides us with enough evidence to conclude that there was a division of tasks between the sexes in these communities.

Apart from Menteşe, bone preservation was in general rather bad and skeletons were incomplete at all sites. Bad skeleton preservation was characteristic especially of Barcın and of the graveyard at Aktopraklık C, the graves of the latter site being close to the modern surface.

Regarding stature, the present study includes supplementary data for stature from Aktopraklık and Barcın to the already published data from the four sites. All data

45 Alpaslan-Roodenberg 2011b.
46 Alpaslan-Roodenberg/Todorova/Petrova 2013.
47 Kanjou *et al.* 2013.
48 Talalay 2004, 140.
49 Alpaslan-Roodenberg/Maat 1999.
50 Molleson 1994.
51 Ibid.; Alpaslan-Roodenberg, 2001; 2008; 2011a.

added together this provides an average of 168.5 cm for males and 153.5 cm for females (appendix: table 3).

These figures are derived from 44 of a total of 131 individuals, and thus one third of the examined adult population; in addition, the sites are unevenly represented. While for example Ilıpınar and Menteşe yielded stature data from the whole male population, Aktopraklık and Barcın were less productive. The reason for this is the state of preservation of the long bones at the various sites, these parts being employed in the standard method for estimating stature. For example, while Aktopraklık yielded the largest human bone collection from the graveyard in area C, damage caused to this sector resulted in a great deal of fragmented skeletons, which explains the low number of measurable bones. The graves of the other three sites, by contrast, were found several meters below the current surface offering better protection against *postmortem* disturbances. Consequently, the high scores of Ilıpınar and Menteşe for stature estimation, but exactly why Barcın offered so few options for determining adult stature and cranial index is an unanswered question (see respectively tables 3 and 1). Most of these stature data were provided by the bone collections from Menteşe and Ilıpınar. Menteşe yielded complete long bones from all adults (11 in total), while from Ilıpınar 13 from 17 adults (more than two third) could be estimated. In contrast, Aktopraklık produced only 15 stature estimations from 66 adults and one adolescent, which is less than one fourth of the adult population. Barcın scored even lower: apart from one adolescent only 8 from 37 examined adults presented measurable long bones for stature estimation. This average stature estimation excludes two individuals from Barcın: male L10E 126 (1) with a stature of 187.9 cm and adolescent (probable male) M11-S 343) with a height of 181.7 cm, because both measurements deviate too much from the average male stature of the Neolithic male population in the eastern Marmara. From Barcın 9 stature estimates were made, 4 males, 4 females and one late adolescent. The females match with the average stature of the region, their height estimation ranging from 146.8 to 159.2 cm. As stated above the male and adolescent were of disproportionate stature, while the other three males with an height between 166.5 and 167.1 cm match the regional stature scores (table 3). If there had only been one male with an exceeding stature estimation, it might have been an outlier. Indeed a puzzling issue. Another problematic stature case came from the Aktopraklık collection. One of the skeletons (19K 37.1'10) found buried in sitting position together with a juvenile, had a height of 170.1 cm. This according to the arm bone measurements (estimation for both sexes), while the upper leg bone measurements of this skeleton indicated a height between 160 (for a female) and 165 cm (for a male). The biological sex of this young individual was not established, neither osteologically nor genetically and her or his height remains indefinite.

Eleven skulls (4 female, 6 male and one unknown sex) could be measured for the cranial index calculations (breadth/length × 100) from Ilıpınar, Menteşe and Aktopraklık[52]. None of the Barcın skulls were included, because all were incomplete. Five mesocranic (2 F, 2 M, one unknown sex), 3 brachycranic (1 F, 2 M) and 3 dolichocranic (1 F, 2 M) skulls were identified among them (table 1 shows additional data from the Aktopraklık and Barcın skeletons)[53].

A health condition common to all four sites was how men as well as women often suffered from osteophytes in their finger bones, a kind of arthritic change developing when one repeats certain physical movements. It is a known fact that people practicing particular occupations contract osteoarthritis at certain joints, but other factors such as obesity can influence its development[54]. At Ilıpınar arthritic changes were found in 4 female and 5 male adults, while at Menteşe it was a common health problem of males. At Aktopraklık adults of both sexes who suffered from this disease were all of middle or old age, most likely as a result of the ageing process. All in all, those who developed osteoarthritis in the villages were in majority males indicating that this bone and joint disease was particularly related to physical tasks of the male population.

Both sexes in all four settlements suffered from dental problems such as caries, periapical abscesses, periodontitis, alveolar bone resorption and calculus formation. At Barcın the calculus level was more advanced in females than in males. As this is generally related to dietary differences, it suggests women there consumed a comparatively larger amount of sticky, cereal-based food, while the diet for men was focused on tougher products such as meat. A majority of children showed heavy dentine exposure at young age even in their milk teeth, which means that already after the weaning period they began to eat the same food as adults. As might be expected, teeth worn down to the extent of dentine exposure were observed in the majority of the adult population, in degrees depending on the age of the individual. In such small communities like Neolithic villages we suppose the same diet for most residents. As a consequence, depending of age, dental wear pattern would be comparable between them. This

52 Alpaslan-Roodenberg 2008; 2001; 2011a respectively.

53 Cranial index is thought to be a good measure to show the completeness of the skeleton in this study as strikingly less calculations could be made for such a huge skeletal collection

54 King *et.al* 2013.

is commonly explained as a result of crushing and grinding food ingredients on millstones. Dust and grit released from these operations is absorbed into the foodstuffs causing strong wear to the dental enamel, a wide spread abrasion phenomenon that has affected people's health for millennia.

In summary, when overviewing the various aspects we have discussed above regarding the four early farming communities in the eastern Marmara region, it is noticeable that there are overall similarities in the health conditions and the way in which the people dealt with the dead. That said, it appears that discrepancies between the communities in the age at death and the use of force were considerable. Any explanation of these factors, in particular the almost lack of infants at Aktopraklık and the bodily violence represented at Barcın and Aktopraklık, will have to be sought in further field research.

Acknowledgment: The first author is indebted to the archaeologists for offering the opportunity to analyze the human remains in the course of seasons and to use the photos from the excavation archives. Both authors express their gratitude towards Ron Pinhasi for commenting on the manuscript, Julian Bennett for major text corrections and to Ben Claasz Coockson for the upgrading of illustrations.

Literature

Alpaslan-Roodenberg 2001: S. Alpaslan-Roodenberg, Newly found human remains from Menteşe in the Yenişehir Plain: The season of 2000. Anatolica 27, 2001, 1–14.

– 2008: –, The Neolithic cemetery. The anthropological view. In: J. Roodenberg/S. Alapaslan-Roodenberg (eds), Life and Death in a Prehistoric Settlement in NW Anatolia. The Ilıpınar Excavations Vol. III. Publications de Stamboul 110 (Leiden 2008) 35–68.

– 2011a: –, A preliminary study of the burials from Late Neolithic-Early Chalcolithic Aktopraklık. Anatolica 37, 2011a, 17–43.

– 2011b: –, Homicide at Aktopraklık, A Prehistoric Village in Turkey. Near Eastern Archaeology 74/1, 2011, 60–61.

–/Maat 1999: S. Alpaslan-Roodenberg/G. J. R. Maat, Human skeletons at Menteşe Höyük near Yenişehir. Anatolica 25, 1999, 37–51.

–/Gerritsen/Özbal 2013a: –/F. Gerritsen/R. Özbal, The Neolithic burials from Barcın Höyük: the 2007–2012 excavation seasons. Anatolica 39, 2013, 93–111.

–/Todorova/Petrova 2013b: M. S. Alpaslan-Roodenberg/N. Todorova/V. Petrova, The human burials of Yabalkovo. Praehistorische Zeitschrift 88/1–2, 2013, 23–37.

Ambade/Fulpatil/Kasote 2017: H. V. Ambade/M. P. Fulpatil/V. P. Kasote, Persistent metopic suture with multiple sutural bones at unusual sites. International Journal of Anatomical Variations 10,3, 2017, 69–70.

Anderson/Loeser 2010: S. Anderson/R. F. Loeser, Why is osteoarthritis an age related disease? Best Practise & Research Clinical Rheumatology, 24/1, 2010, 15–26.

Aspoeck 2008: E. Aspoeck, What Actually is a 'Deviant Burial'? Comparing German-Language and Anglophone Research on 'Deviant Burials'. In: E. M. Murphy (ed.), Deviant burial in the archaeological record (Oxford 2008) 17–34.

Aufderheide/Rodriguez-Martin/Langsjoen 1998: A. C. Aufderheide/C. Rodriguez-Martin/O. Langsjoen, The Cambridge Encyclopedia of Human Paleopathology (Cambridge 1998).

Brothwell 1981: D. R. Brothwell, Digging up bones: the excavation, treatment and study of human skeletal remains (Ithaca, New York 1981).

Budhiraja/Rastogi/Anjankar *et al.* 2013: V. Budhiraja/R. Rastogi/V. Anjankar/C. S. R. Babu/P. Goel, Supernumerary renal arteries and their embryological and clinical correlation: a cadaveric study from north India. Published online 2013 Feb 20. doi: 10.5402/2013/405712

Buikstra/Ubelaker 1994: J. Buikstra/D. H. Ubelaker, Standards for Data Collection from Human Skeletal Remains. Arkansas Archaeological Survey Report 44 (Fayetteville 1994).

Duday 2014: H. Duday, The Archaeology of the Dead. Lectures in Archaeothanathology (Oxford, Philadelphia 2014).

Fazekas/Kosa 1987: I. Gy. Fazekas/F. Kosa, Forensic fetal osteology. Akadamiai Kiado (Budapest 1987).

French 1967: D. H. French, Prehistoric sites in Northwest Anatolia. I. The İznik area. Anatolian Studies 17, 1967, 49–100.

Gerritsen/Özbal 2014: F. Gerritsen/R. Özbal, 2012 yılı Barcın Höyük kazısı. Kazı Sonuçları Toplantısı 35/1, 2014, 471–485.

Göksu/Timms 1999: S. Göksu/E. Timms, The Life and Work of Nazim Hikmet (New York 1999).

Hofmanova 2016: Z. Hofmanova, Palaeogenomic and Biostatistical Analysis of Ancient DNA Data from Mesolithic and Neolithic Skeletal Remains (Unpublished Dissertation. Johannes Gutenberg University, Mainz 2016).

Kanjou/Kuijt/Erdal *et al.* 2013: Y. Kanjou/I. Kuijt/Y. S. Erdal/O. Kondo, Early human decapitation, 11,700–10,700 cal BP, within the Pre-Pottery Neolithic Village of Tell Qaramel, North Syria. International Journal of Osteoarchaeology, DOI: 10.1002/oa.2341. 10 p.

Karul/Avcı 2013: N. Karul/M. B. Avcı, Aktopraklık. In: M. Özdoğan/N. Başgelen/P. Kuniholm (eds), The Neolithic in Turkey. New excavations and new research. NW Turkey and Istanbul. Archaeology and Art Publications (Istanbul 2013) 45–68.

– 2018: –, Aktopraklık, Tasarlanmış Prehistorik Bir Köy (Istanbul 2018)

Kızıltan/Polat 2013: Z. Kızıltan/M. A. Polat, The Neolithic at Yenikapı Marmaray: Metro Project Rescue Excavations. In: M. Özdoğan/N. Başgelen/P. Kuniholm (eds), The Neolithic in Turkey. New excavations and new research. NW Turkey and Istanbul. Archaeology and Art Publications (Istanbul 2013) 113–165.

King/March/Anandacoomarasamy 2013: L. K. King/L. March/A. Anandacoomarasamy, Obesity & Osteoarthritis. Indian Journal of Medical Research 138/2, 2013, 185–193.

Krogman/İşcan 1992: W. M. Krogman/M. Y. İşcan, The human skeleton in forensic medicine (New York 1992).

Mann/Murphy 1990: R. W. Mann/S. R. Murphy, Regional atlas of bone disease: A guide to pathologic and normal variation in the human skeleton (Springfield, Illinois 1990).

Maresh 1970: M. M. Maresh, Measurements from roentgenograms. In: R.W. McCammon (ed.), Human growth and development (Springfield IL. 1970) 157–200.

Mathieson/Lazaridis/Rohland *et al.* 2015: I. Mathieson/I. Lazaridis/N. Rohland, Genome-wide patterns of selection in 230 ancient Eurasians. Nature 528, 2015, 499–503. (Paper/Supplementary Materials/PMCID:PMC4918750)

Molleson 1994: T. Molleson, The eloquent bones of Abu Hureyra. Scientific American 271/2, 1994, 70–75.

Roberts/Manchester 1995: Ch. Roberts/K. Manchester, The Archaeology of Disease (Ithaca, NY 1995).

Roodenberg 1999: J. Roodenberg, Investigations at Menteşe Höyük in the Yenişehir basin (1996–97). Anatolica 25, 1999, 21–35.

– 2012: –, Change in food production and its impact on an early 6th millennium community in northwest Anatolia. The example of Ilıpınar. Praehistorische Zeitschrift 87/1–2, 2012, 93–111.

– 2019. –, Adaptation as a *constante* in early farming village economy – an eight thousand years old case. In: A. Marciniak (ed.), Concluding the Neolithic: The Near East in the second half of the seventh millennium BCE (Atlanta 2019) 241–256.

van As/Alpaslan-Roodenberg 2008: –/A. van As/S. Alpaslan-Roodenberg, Barcın Höyük in the Plain of Yenişehir (2005–2006). A preliminary note on the fieldwork, pottery and human remains of the prehistoric levels. Anatolica 34, 2008, 53–60.

Rotschild/Martin 1993: B. M. Rotschild/L. D. Martin, Paleopathology: Disease in the fossil records (Florida 1993).

Sahajpal/Pichora 2006: D. T. Sahajpal/D. Pichora Septal aperture: an anatomic variant predisposing to bilateral low-energy fractures of the distal humerus. Canadian Journal of Surgery 49, 2006, 363–364.

Schaeffer/Black/Scheuer 2009: M. Schaeffer/S. Black/L. Scheuer, Juvenile Osteology: a laboratory and field manual (Amsterdam, Boston 2009).

Skoglund/Stora/Götherström *et al.* 2013: P. Skoglund/J. Stora/A. Götherström/M. Jakobsson, Accurate sex identification of ancient human remains using DNA shotgun sequencing. Journal of Archaeological Science 40, 2013, 4477–4482.

Steckel/Larsen/Walker 2006: R. H. Steckel/C. S. Larsen/P. L. Walker, The Global History of Health. Data Collection Codebook. http://global.sbs.ohio-state.edu/ Accessed May 17, 2006.

Talalay 2004: L. Talalay, Heady business – skulls, heads and decapitation in Neolithic Anatolia and Greece. Journal of Mediterranean Archaeology 17/2, 2004,139–163.

Trotter/Gleser 1952: M. Trotter/G. C. Gleser, Estimation of stature from long bones of American whites and negroes. American Journal of Physical Anthropology 10, 1952, 463–514.

–/– 1958: –/–, A re-evaluation of estimation of stature based on measurements of stature taken during life and of long bones after death. American Journal of Physical Anthropology 16, 1958, 79–123.

Turetsky/Vines/Clayman 1990: D. B. Turetsky/F. S. Vines/D. A. Clayman, Surfer's ear: Exostoses of the external auditory ear. American Journal of Neuroradiology 11/6, 1990, 1217–1218.

Ubelaker 2008: B. Ubelaker, The houses from Ilıpınar X and VI compared. In: J. Roodenberg/S. Alapaslan-Roodenberg (eds), Life and Death in a Prehistoric Settlement in NW Anatolia. The Ilıpınar Excavations Vol. III. Publications de Stamboul 110 (Leiden 2008) 149–203.

Ubelaker 1978: D. H. Ubelaker, Human skeletal remains. Excavation, analysis, interpretation. Taraxacum (Washington D.C. 1978).

– 2002: –, Approaches to the Study of Commingling in Human Skeletal Biology. In: W. D. Haglund/M. H. Sorg (eds), Advances in Forensic Taphonomy: Method, Theory, and Archaeological Perspectives (Boca Raton 2002) 355–378.

White/Black/Folkens 2012: T. D. White/M. T. Black/P. A. Folkens, Human Osteology (Oxford 2012).

WEA 1980: Workshop of European Anthropologists (WEA). Recommendations for age and sex diagnosis of skeletons. Journal of Human Evolution 9, 1980, 390–404.

Appendix

Tab. 1: Demographic distribution of Aktopraklık and Barcın individuals (additional data)

Demographic Distribution						
Burial Code	**Sex**	**Age**	**Stature cm**	**bone**	**Cephalic Index index breadth/length × 100**	**form**
Aktopraklık						
Subadult						
19K 146'13	infant	1,5 yrs				
19K 35.2'10	juvenile	3–3,5 yrs				
19K 33.3'10	juvenile	3–3,5 yrs				
19K 49'10	juvenile	3–3,5 yrs				
19K 67.1'11	juvenile	7 yrs				
19K 67.2'11	juvenile	3–4 yrs				
18K 27.2'15	juvenile	11 yrs				
19K 120'12	juvenile	indet				
19K 37.1'10	adolescent	16–18 yrs	166.2 M	L humerus	79.2	mesocephalic
			160.4 F	L humerus		
			170.1 M	R radius		
			170.1 F	R radius		
			164.8 M	R femur		
			159.8 F	R femur		
Adult						
92D 102.1'10	F?	17–25 yrs				
90E 13'10	F?	35–45 yrs	156.6	R+L tibia		
90E 6'10	F?	35–45 yrs				
92D 101'10	M	middle-old				
92D 102.2'10	M?	25–35 yrs				
88D 106'10	F?	25–35 yrs	154.3	R femur		
90E 16'10	F	middle-old				
88F 15.1'09	M?	old				
89D 25'09	F?	middle aged				
89F 17.5'09	indet.	adults				
88F 13'09	F?	25–35 yrs				
89F 20.1'10	M?	adult				
89F 21.1'09	F?	25–35 yrs				
19I 97'13	F?	middle-old				
18L 58'11	M?	middle aged	163.6	L femur	79.3.	mesocephalic
19M 7.1'10	M?	middle aged				
19K 35.1'10	M	25–35 yrs	171.8	L radius		
19K 120'12	F?	adult				
19K 87'11	F	35–45 yrs	143.0	R+L femur		
21K 21'11	F and M	adult				
Barcın						
Subadult						
M10 287	prenatal	32 weeks				
M11 352	prenatal	34–36 weeks				
M11 352	prenatal	36–38 weeks				
M11 352	prenatal	36–38 weeks				
M11 352	prenatal	38 weeks				
L11 S 488	neonatal	38–40 weeks				
M11 271	prenatal	37–38 weeks				
L10W(E)117	neonatal	38–40 weeks				
M11 354	neonatal	38–40 weeks				
M11 S 350	neonatal	40 weeks				

Tab. 1 (continued)

Demographic Distribution						
Burial Code	**Sex**	**Age**	**Stature cm**	**bone**	**Cephalic Index index breadth/length × 100**	**form**
M11 280	neonatal	38–40 weeks				
L10 E 106.1	infant	3 months				
L14 202	prenatal	38 weeks				
L11 214	juvenile	8 yrs (R ulna)				
L11 605	juvenile	12–13 yrs				
M11 S 343.1	indet	15–17 yrs	181.7	R radius		
Adult						
L10W(E)117	indet	middle aged				
M11 S 335	indet	35–45 yrs				
M11 S 435	M	25–35 yrs				
M11 S 401	F?	30–45 yrs				
L10E 126.1	M	25–35 yrs	187.9	L humerus		
L10 E 126.2	F	old	152.9	L ulna		
M13 183	F	25–35 yrs				
L10E 106.2	F?	middle aged				
L10E 106.3	M?	indet				
L10 E 173	M	25–35 yrs				
L11 W 546	neutral	35–45 yrs				
L11 583.1	M	25–35 yrs				
L11 583.2	indet	older				
M11-S 345	F	25–35 yrs				
M13 119	M	25–35 yrs	173.1	L radius		
M11 S 343.2	F?	middle-old				
L11N 451.1	M	middle-old				
L11N 451.2	F	indet				
M13 171	F	20–35 yrs				

Cephalic index and stature were added in the table when available. F?/M? = probable female/male.

Tab. 2: Trauma, injury and health condition of Aktopraklik and Barcın populations (additional data)

Pathology			
Pathology/ Variation/ Trauma	**Definition**	**Site**	**Burial Code**
Skeletal Pathology			
OA			
	Osteophytes of the lumbar vertebral bodies	Akt	90E 13'10
	Arthritic changes of the manubriosternal joint	Akt	92D 101'10
	Osteophytes of the sternal facet of left clavicle		
	Osteophytes on the hand phalanges	Akt	92D 102.1'10
	Achilles tendon enthesopathy	Akt	88D 106'10
	Sacroiliac joint fusion; left side	Akt	90E 16'10
	Achilles tendon enthesopathy	Akt	88F 15.1'09
	Osteophytes of the 1,2,3. lumbar vertebral bodies	Akt	18L 58'11
	Porotic lesions in the scapula		
	Pitting on the sternoclavicular joint surface of the left clavicle		
	Both calcaneus exhibited calcaneal spur		
	left calcaneus exhibited a fossa (horizontal length 16 mm, vertical 25mm)		
	Small bony projections/enthesophytes on the superoanteriorface of the left and right patellas		
	Enthesophytes of the superoanterior surface of patellas		
	Achilles tendon enthesopathy	Akt	19K 35.1'10
	Achilles tendon enthesopathy	Barcın	M11-S 335
	Vertebral spinal osteophytes	Barcın	M11-S 401
	Porotic lesions on the right caput femoris	Barcın	L10 E 126.1
	Osteophytes of the lumbar vertebral bodies	Barcın	L10 E 126.2
	Osteophytes of the thoracic vertebral bodies		
	Osteophytes on the hand phalanges		
	Osteophytes on the hand phalanges	Barcın	L10 E 173
	First metacarpales		
	Porotic lesions on the left femur proximal		
	Osteophytes around the margin of the cubocalcaneal joint of the right calcaneus		
	Osteophytes and porotic lesions on the vertebral bodies	Barcın	L11 W 546
	Porotic lesions on the acetabulum (pelvis)	Barcın	M11-S 345
	Porotic lesions on the right femur proximal		
	Achilles tendon enthesopathy		
	Osteophytes of the right patella	Barcın	M13 119
	Porotic lesions and osteophytes on the femur prox	Barcın	M11 -S 343.1
	Slight porotic lesions on the left and right distal radius		
	Porotic lesions on the right clavicle	Barcın	L11 N 451.1
	Porotic lesions on the sternum (anterior and posterior)		
	Osteophytes on the hand phalanges		
Degenerative arthritis			
	Porotic lesions on the vertebral bodies	Akt	19K 37.1'10
	Porotic lesions on the proximal part of the left femur		
	2 fused thoracic vertebrae	Barcın	M13 171
Porotic hyperostosis	Frontal bone	Akt	18L 58'11
	Occipital bone	Barcın	M11-S 335
	Occipital and partly parietal	Barcın	M11-S. 435
	Occipital and parietal	Barcın	M11-S 401
	Occipital and left parietal	Barcın	L10 E 106.2
	Parietal frg.	Barcın	L10 E 173
	Occipital	Barcın	L11 583.1
	Parietal	Barcın	M11-S 345
	whole skull	Barcın	M11 S 343.2

Tab. 2 (continued)

Pathology/ Variation/ Trauma	Definition	Site	Burial Code
Cribra orbitalia	Left orbit	Barcın	L10 E 173
	Right orbit	Barcın	M11-S 345
	Left and right orbits	Barcın	M11 S 343.2
Vastus notch	Superolateral angle of the right patella	Akt	89F 21.1'09
	Medial vastus notch on the left patella	Akt	19K 37.1'10
	Left patella	Barcın	M11-S 401
	Right patella		M13 119
Vastus fossa	Along the superolateral margin of both patella	Akt	18L 58'11
Bipartite patella	Right patellae	Akt	89F 21.1'09
Metopic suture		Akt	19M 7.1'10
Wormian bones	Left and right sides of the occipital bone	Akt	19M 7.1'10
Septal aperture	Left side	Akt	88D 106'10
	Right side	Akt	89F 20.1'10
	Left and right	Barcin	L10 E 126.1
Supra orbital foramen	Left and right sides	Akt	88F 15.1'09
Squatting facet	Right and left talus; left tibia	Akt	90E 13'10
	Right talus and right tibia	Akt	19K 35.1'10
	Right talus	Barcın	M11-S 401
	Right tibia and right talus	Barcın	M11-S 345
Schmorl nodule	Lumbar vertebrae 1,2,3	Barcın	L10 E 173
Cortical defect	Right and left femora distal part	Akt	90E 13'10
Mandibular lesion	Widening of the left mandibular canal	Akt	88F 13'09
Osteoma	Exostosis of the right ear canal	Akt	88F 13'09
Bone resorption	Mandibular	Akt	88F 15.1'09
Calcaneal spur	Right side	Barcın	M11-S 345
Ligament ossification	Right calcaneus: dorsal calcaneocuboid ligament ossification.	Barcın	M11-S 345

Trauma/injury

Bone	Type of injury	Healing mark	Dimensions of the injury		
Left parietal	small cut marks made by a sharp object	none		Akt	90E 13'10
Femur and tibia frgs.; cut marks		none		Akt	88F 15.1'09
The medial margin of the left patella		yes		Akt	18L 58'11
Lower end of the right fibula; cut mark made by a sharp object		none	83mm length		
Skull fractures (postmortem?)		none			
Frontal, parietal; cut marks		none		Akt	19M 7.1'10
Left parietal	small notch	none	6.8mm width	Akt	19K 40'10
Left parietal	small notch	none	6.8mm width	Akt	19K 33.3'10
Cut marks on the skulls of the children 40 and 33.3 (19K, 2010) were made probably by a similar object.					
Occipital	4 cut marks	none	Between 6.2- 8.7 mm	Barcın	L10 E 106.2
Femur distal cut mark		none	46.7 mm length	Barcın	L10 E 106.3
Sternum anterior		started	length: 14.80 mm width: 4.16 mm (largest point)	Barcın	L10 E 173
3. lumbar vertebra	cut mark	none	length 38 mm width: 11 mm	Barcın	M11-S 345

Tab. 2 (continued)

Pathology/ Variation/ Trauma	Definition			Site	Burial Code
3 carpal bones round holes		none	the biggest hole: 2.81 length, width 3.5 mm		
Left ilium a hole by penetration of a sharp pointed object			Length: 14.46 mm, width: 2.38 mm		
Iliium	a hole by a penetration of a sharp object	none	length 75.76. width 16.23 mm	Barcın	M13 119
Saggital suture (skull) 3 holes	Carnivore tooth marks?	none		Barcın	M11 S 343.2
Right femur distal cut marks by a sharp object		none	length 54.06mm 12.44mm	Barcın	M13 171

Dental condition **Aktopraklık**

Burial Code N inspected		AM loss	Caries Period. Dis.	Alv. Atrophy	Calculus	At. Ctl.	Special features
90E 6'10	4			advanced	moderate		
92D 102.1'10	19						
92D 102.2'10	5	isolated					
88D 106'10	9				moderate		
88F 15.1'09	8	6 mandibular molars					
89D 25'09	3						
88F 13'09	21	LLM1,LLM2, LRM2	URM3			Sulcus/dental wear URC buccolingual LRP, C deeply worn P1, P2 worn mesiodistally	
89F 21.1'09	24				moderate	URM3 (Ctl.)	UL between C and P1
19 I 97'13	22	URP1, LRM3, LLM2		moderate to considerable	moderate		
18L 58'11	27	LM1, LP2, RM1			moderate		
19K 87'11	5			moderate			
19M 7.1'10	2						
19K 40'10 subadult		22= 15 deciduous 7 permanent					dental wear
19K 35.1'10	28	LRP1			slight		
19K 37.1'10	16						
19K 33.3'10 subadult		23= 15 deciduous, 8 permanent				LRI1 deciduous (At.) LRI2 enlarged	dental wear UR and L m1 red coloured

Tab. 2 (continued)

Pathology/ Variation/ Trauma	Definition					Site	Burial Code
Dental condition				**Barcın**			
M11-S 335	29		4	advanced to moderate	moderate		
M11-S 435	31		2	moderate	advanced		
M11-S 401	26	LRM1	1	moderate	moderate		
L10 E 126.1	32		2	slight	slight		
L10 E 126.2	1	R M1,2,3					
M13 183	29	ULP2,ULM1		moderate	moderate		
L10E 106.2	5						
L10 E 173	30	isolated			slight		
L11 W 546		moderate level of periodontal disease			advanced	LLM3 (Ctl.)	
L11 583.1				slight	slight		
L11 583.2			many	advanced			
M11 S 345	32						
M13 119	31			moderate to advanced	slight		
M11 S 343.1	29						
M11 S 343.2	30				moderate	LLM3, LRM3 (Ctl.)	
L11 N 451.1	19	LRM1, LLM1		slight	slight	LRM3(Ctl.)	
M13 171	31						

Abbreviations: OA = Osteoarthritis, Frg = Fragment, Akt = Aktopraklık, At = Antemortem missing tooth, Ctl = Congenitally missing tooth

Tab. 3: Mean values of calculated stature from contemporary sites in the Eastern Marmara region.

	Female		Male	
Site	**N**	**S**	**N**	**S**
Ilıpınar	8	154.3 cm	5	168.9 cm
Menteşe	6	154 cm	5	168 cm
Barcın	4	152.3 cm	3	168.9 cm
Aktopraklık	5	153.6 cm	9	168.2 cm
NW Anatolia	23	153.5 cm	22	168.5 cm

N = Total number of individuals, S = Stature.
All estimations were made according to the regression formulas of Trotter and Gleser, 1952, 1958 for whites.